

# Degeneración hepatocerebral adquirida: una rara complicación neurológica de la cirrosis hepática

## *Acquired hepatocerebral degeneration - a rare neurological complication of liver cirrhosis*

Catarina Medeiros, Rita Serras Jorge

Centro Hospitalar do Médio Tejo (Portugal)

**Keywords:** Hepatocerebral degeneration; liver cirrhosis; manganese.

**Palabras clave:** Degeneración hepatocerebral; cirrosis hepática; manganeso.

We reported a 64-years-old woman with medical history of hepatic cirrhosis caused by Hepatitis B and Hepatitis C virus, Child-Pugh Score 8 (Class B), with portal hypertension, ascites suppressed with diuretics, esophageal varices grade II and hypertensive gastropathy, that presents with seven months history of subacute-onset hand tremor and postural imbalance. Neurological examination showed bilateral extreme nystagmus, rest and kinetic hand tremor, doubtful Romberg test and slightly enlarged base gait. Dosage of ammonia was normal. Others causes of neurological disease in cirrhotic patient has discharged. MRI showed homogenously increased T1 signal within the basal ganglia (nucleus pallidus), with normal T2-weighted, associated to manganese accumulation. The diagnose of Acquired hepatocerebral degeneration was made. The patient was forwarded to pre-transplant appointment and Neurology. After pre-transplant appointment the patient was not considered as a transplant candidate and was discharged. The patient was assessed in the Neurology appointment and was decided to maintain medication with propranolol 40 mg twice a day. At this date the patient was three years of the diagnose of acquired hepatocerebral degeneration without worsening of the neurological symptoms.

Acquired hepatocerebral degeneration is a rare and debilitating neurological syndrome, characterized by movement disorders and cognitive impairment in cirrhosis or portosystemic shunts<sup>1,2</sup>. Bilateral hyperintensity in the globus pallidus on T1-weighted sequences, with normal T2-weighted are the most common abnormal finding<sup>3</sup>. It is a consequence of manganese deposition in nucleus ganglia<sup>3</sup>. Medical treatments are not effective<sup>2</sup>. Liver transplantation showed good outcomes<sup>2</sup>.

### CONFLICT OF INTEREST

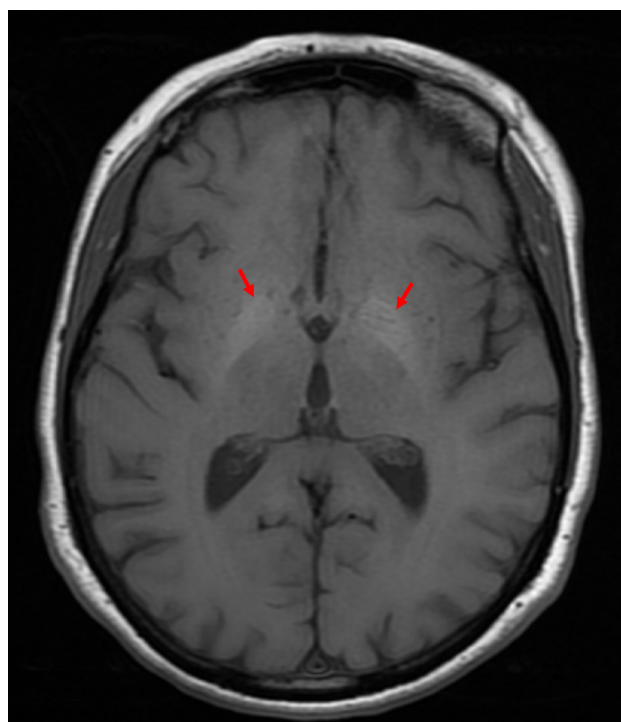
The authors declare that there is no conflict of interest in this work.

### SOURCE OF FUNDING

This research had no funding sources.

### ETHICAL ASPECTS

All participants submitted a consent form to be included in this study.



## REFERENCES

1. Sureka B, Bansal K, Patidar Y, Rajesh S, Mukund A, Arora A. Neurologic Manifestations of Chronic Liver Disease and Liver Cirrhosis. *Current Problems in Diagnostic Radiology*. 2015;44(5):449–61.
2. Shin H-W, Park HK. Recent Updates on Acquired Hepatocerebral Degeneration. *Tremor Other Hyperkinet Mov (N Y)*. 2017;7:463.
3. Maffeo E, Montuschi A, Stura G, Giordana MT. Chronic acquired hepatocerebral degeneration, pallidal T1 MRI hyperintensity and manganese in a series of cirrhotic patients. *Neuro Sci*. 2014;35(4):523–30.

Correspondencia: catarinafernandesmedeiros@gmail.com

Cómo citar este artículo: Medeiros C, Serras R

Degeneración hepatocerebral adquirida: una rara complicación neurológica de la cirrosis hepática. *Gaceta Clin* 2023; 84-1: 46

Recibido: 20/01/2022 ; Aceptado: 23/02/2022 // <https://doi.org/10.22546/68/2766>