

Un quiste ovárico gigante enmascarado como ascitis

A giant ovarian cyst masked as ascites

Ana Luísa Figueiredo Albuquerque, Juliana Silva

Department of Internal Medicine. Centro Hospitalario de Leiria (Portugal)

ABSTRACT

Ovarian cysts are a very commonly encountered condition in females, about 7% of women are reported to have an ovarian cyst at any point in their life.¹ We present the case of a 78-year-old woman, referred to our consult for the study of ascites. The Abdominal-pelvic CT revealed a massive ovarian cystic tumor, that was submitted to surgery and drainage of approximately 30L (40Kg).

Keyword: ascites; benign tumor; giant cyst; pelvic mass.

CASE DESCRIPTION

We present the case of a 78-year-old woman, referred to a medical appointment for the study of ascites. The patient mentioned increased abdominal perimeter with more than 12 years of evolution. No toxicological, smoking or alcoholic habits.

Physical examination revealed pink conjunctivae and anicteric sclerae. Her vital parameters were normal, and her weight was 100 kg. She presented a very globose abdomen with collateral circulation, slightly depressed on palpation, with dullness on percussion and the presence of an ascitic wave. The presence of edema in both lower limbs should be highlighted.

Blood analysis revealed mild normocytic, normochromic anemia (hemoglobin 10,2 g/dL), and an isolated elevation of tumor marker Ca125 (157 U/mL).

Abdominal-pelvic CT showed a large, well-defined, and homogeneous fluid formation, occupying practically the entire upper abdomen and pelvis, probably related to an ovarian cystic tumor, measuring approximately 43.2 cm in the sagittal plane (Figure 1 and 2).

The patient was referred to Gynecological Oncology, and underwent exploratory laparotomy, in which an adnexal tumor measuring approximately 70x40 cm was identified, with multiple adhesions to intestinal loops, which made surgical recession impossible. The drainage of the cystic content was performed, with an outflow of approximately 30L of gray-green content (40 kg). The biopsy material consisted of fibrosis associated with a chronic inflammatory process, and the patient are under surveillance.

Routine physical examinations and imaging have enabled clinicians to diagnose ovarian cysts at a relatively smaller size.^{1,2} Giant ovarian cysts, which are generally described as more than 10 centimeters in size in their largest diameter and are rare in occurrence.^{1,3} This case report emphasizes that cystic ovarian tumors could present masquerading as an ascites.

Correspondencia: luisaana1991@gmail.com

Cómo citar este artículo: Figueiredo Albuquerque AL, Silva J

A giant ovarian cyst masked as ascites. *Galicía Clin* 2022; 83-4: 66-66

Recibido: 29/06/2021 ; Aceptado: 10/08/2021 // <https://doi.org/10.22546/67/2686>

RESUMEN

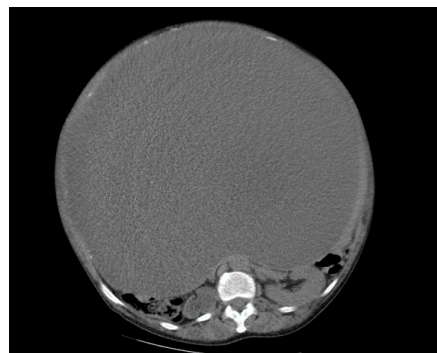
Los quistes ováricos son una condición muy común en mujeres, alrededor del 7% de las mujeres reportan tener un quiste ovárico en algún momento de su vida.¹ Presentamos el caso de una mujer de 78 años, referida a nuestra consulta para el estudio de la ascitis. La TC abdominopélvica reveló un tumor quístico ovárico masivo, que fue sometido a cirugía y drenaje de aproximadamente 30L (40Kg).

Palabras clave: ascitis; tumor benigno; quiste gigante; masa pélvica.

Figure 1

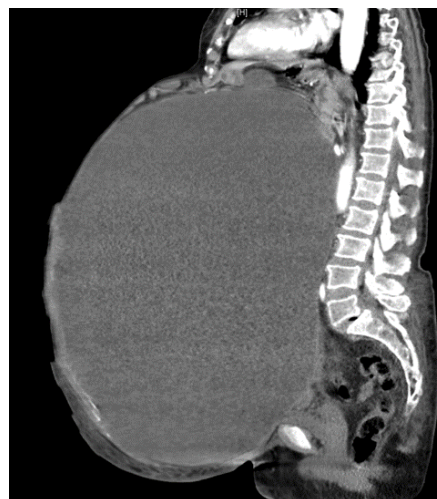

Figure 2



REFERENCES

1. Albers CE, Ranjit E, Sapra A, Bhandari P, Wasey W. Clinician Beware, Giant Ovarian Cysts are Elusive and Rare. *Cureus*. 2020;12(1).
2. Yeika EV, Efié DT, Tolefac PN, Fomengia JN. Giant ovarian cyst masquerading as a massive ascites: A case report. *BMC Res Notes*. 2017;10(1):8-11.
3. Fatema N, Mubarak Al Badi M. A Postmenopausal Woman with Giant Ovarian Serous Cyst Adenoma: A Case Report with Brief Literature Review. *Case Rep Obstet Gynecol*. 2018;2018:1-4.