

Enfermedad de Still Del Adulto y Síndrome de Schnitzler: ¿formas distintas del mismo espectro de enfermedad? Un caso de urticaria y fiebre recurrente en el anciano

Adult-Onset Still's Disease and Schnitzler Syndrome: distinct forms of the same disorder spectrum? – a case of recurrent urticaria with fever in the elderly

Andreia de Matos, Flávia Cunha, Patrícia Dinis Dias

Coimbra Hospital and University Center. Portugal

ABSTRACT

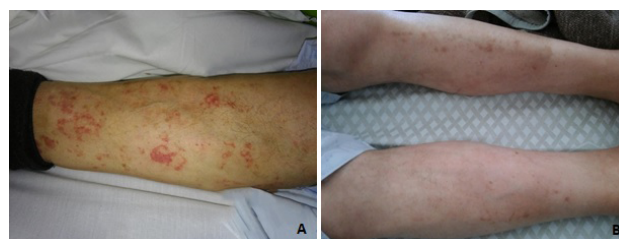Adult-onset Still's disease (AOSD) and Schnitzler syndrome (SchS) are rare, not fully understood, multisystemic and autoinflammatory disorders, with a challenging differential diagnosis. The authors report the case of an elderly man with unexplained fever, arthralgia, weight loss, spleen enlargement, lymphadenopathy, anemia, hyperferritinemia and IgG monoclonal gammopathy. Autoimmunity, infection, haematological disease and malignancy were excluded. The clinical spectrum fulfilled both AOSD diagnostic criteria and IgG-variant SchS Strasbourg criteria. Symptom resolution was achieved with immunosuppressive therapy, supporting the diagnosis of an autoinflammatory disorder, a diagnostic challenge for the medical team emerging as an unexpected cause of fever in the elderly.

Keywords: AOSD; Autoinflammatory disorder; Fever of undetermined origin, Schnitzler syndrome.

CASE PRESENTATION

In March 2017, an 82-year-old Caucasian male was admitted to the Internal Medicine Department with a 4-week history of painless, urticariform rash on the lower limbs and back, with no association with exercise, stress, food, temperature, alcohol intake or contact. Additionally, he described intermittent bilateral asymmetric and inflammatory medium joint polyarthralgia, thoracic pain, fatigue, unintentional weight loss, and nocturnal sweating. Antihistaminic and prednisolone 0.25 mg/Kg/day have been prescribed without resolution. His medical records disclosed moderate thrombocytopenia, heart failure, gout, dyslipidemia and arterial hypertension. He was chronically medicated with a statin, digoxin, diuretic, aspirin, angiotensin-converting enzyme (ACE) inhibitors, calcium channel blockers, allopurinol and nonsteroidal anti-inflammatory drug (NSAID), with no previous known allergies. He was a farmer, without animal contacts. His family history was unremarkable. Physical examination revealed annular, non-palpable purpuric rash on the extensor face on the lower limbs (figure-1A) and confluent urticariform lesions on the back with neither palmoplantar involvement nor angioedema. He was febrile (maximum 39.3°C) at least once a day during the first week of hospitalization. There were no ocular symptoms, oral or genital ulcers, malar rash, photosensitivity, or discoid lesions. He had no signs of arthritis, thyroid nodules or palpable lymph nodes. Neurological exam was normal.

Figure 1. A) Annular and non palpable purpuric and violaceous rash on extensor face on the lower limbs at hospital admission and B) After a few days of antihistaminic therapy with resolution of cutaneous lesions with residual mild hyperpigmentation. The patient gave permission to reproduce his photos, although he could not be identifiable.



DIFFERENTIAL DIAGNOSIS MANAGEMENT

Laboratory tests (table 1) revealed anemia, neutrophilia, thrombocytopenia, elevated C-reactive protein and normal age-adjusted erythrocyte sediment rate. He had severe vitamin D deficiency with hypocalcemia. Renal function, muscular enzymes and thyroid profile were normal. Lactate dehydrogenase, transaminases and ferritin were increased. Haemolysis was unsuspected after normal bilirubin, Coombs test and blood smear.

Infection

Cultures and serological tests came up negative. Chest radiography was normal. Abdominal ultrasound showed spleen enlargement.

Autoimmune disorders

Autoimmune profile and rheumatoid factor were negative. Anti-ds-DNA and complement fraction were normal and urinalysis showed no haematuria or proteinuria (table 1). The absence of cold-induced lesions and negative cryoglobulin excluded cryoglobulinaemic vasculitis. The patient had no proximal muscle weakness, heliotrope rash, Gottron's papules or Holster sign.

Similarly, the absence of mucous ulcers and ocular involvement with non-typical skin lesions excluded Behcet's disease.

Malignancy

An underlying neoplastic disorder was considered. Immunofixation revealed λ -IgG monoclonal gammopathy, with normal total protein, Bence-Jones proteinuria, Igs (M, A and E), and free light chains (table 1). Osteosclerotic myeloma was improbable cause

of monoclonal gammopathy in this patient given the absence of polyneuropathy, a mandatory diagnosis criteria in this condition. Castelman disease usually presents polyclonal B-lymphocytes proliferation. Bone marrow biopsy showed perivascular κ and λ -chains and small B and T-lymphocytes, without hemophagocytosis or malignancy suspicion. Computed tomography (CT) showed mild bilateral pleural effusion and homogeneous splenic enlargement (17x7cm), without hepatomegaly or lymphadenopathy. An 18-FDG-PET scan disclosed bone marrow and millimetric generalized lymph nodes uptake. Gastrointestinal endoscopy was clear.

Table 1. Laboratory analysis performed during patient hospitalization

Laboratory analysis (units)	Results	Normal range
Hemoglobin (g/dL)	9.9	11.8-15.8
Mean corpuscular volume (fl)	84	80-101
White blood cells (x10 ⁹ /L)	12.5	4.0-10.0
Neutrophils (x10 ⁹ /L)	11.5	2.0-7.0
Platelets (x10 ⁹ /L)	90	140-385
Erythrocyte sedimentation rate (mm/h)	38	1-20
Creatinine (mg/dL)	0.8	0.72-1.18
Calcium (mg/dL)	7.8	8.8-10.6
25-Hydroxy vitamin D (ng/mL)	8.7	>29
Parathormon (pg/mL)	94.4	9-72
Sodium (mmol/L)	140	136-146
Potassium (mmol/L)	4.0	3.5-5.1
Magnesium (mg/dL)	2.0	1.8-2.6
C- Reactive protein (mg/dL)	11.5	<0.5
Alanine transaminase (U/L)	110	<45
Aspartate transaminase (U/L)	100	<35
Gamma-glutamyltransferase (U/L)	16	<55
Alkaline Phosphatase (U/L)	71	30-120
Total bilirubin (mg/dL)	0.4	0.2-1.2
Lactate dehydrogenase (U/L)	660	<248
Ferritin (ng/mL)	6291	21-275
Thyroid-stimulating hormone (nUI/mL)	2.2	0.4-4.0
T4 Hormone (ng/dL)	1.2	0.7-1.5
Total protein (g/dL)	5.9	6.6-8.3
G-Immunoglobulin (g/L)	6.76	7.0-16.0
λ -light chain (g/L), kappa/lambda ratio	5.06 (k/ λ 0.84)	2.99-6.99 (k/ λ 1.35-2.65)
Infectious evaluation: HIV antibodies, HAV IgM/IgG, HBsAg, HBsAb, HbCAb IgM, HCV IgM/IgG, EBV IgM, CMV IgM, syphilis, Coxiella burnetti IgG, Brucella spp IgG, Borrelia burgdoferi, Mycoplasma pneumoniae, Leishmania spp bone marrow culture, blood and urine cultures	Negative	---
Autoimmune evaluation: anti-CCP IgG, thyroid peroxidase (TPO) antigen, thyrotropin receptor antibodies (TRAb), antinuclear antibodies, anti-ds- DNA, C-3 and C4 complement, anti- SSA60,SSB,Sm,RNP,Sc170, JO1, cryoglobulin, anti-c-ANCA, anti-P- ANCA, anti-glomerular basement membrane, rheumatoid factor	Normal/ negative	---

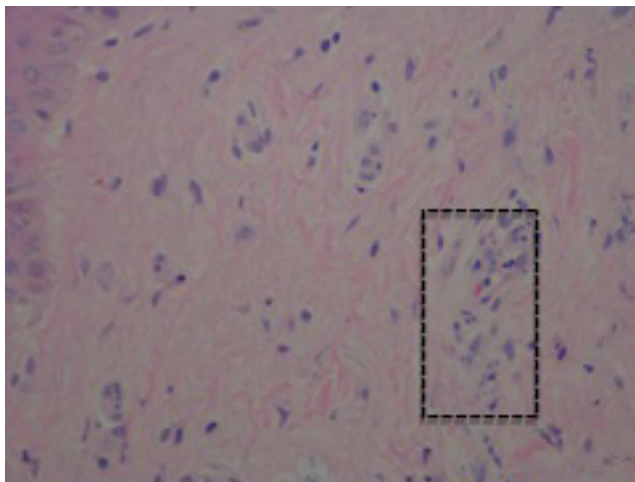
Autoinflammatory diseases

This group of disorders, which includes AOSD and SchS, are usually a diagnosis of exclusion. Considering the presence of fever, rash, arthralgia, neutrophilia, and hyperferritinemia, AOSD was suspected. However, due to urticarial eruptions, monoclonal gammopathy, and systemic inflammation, IgG-variant SchS could not be excluded. No bone remodelling was identified on technetium-99m scintigraphy. After exclusion of infection, allergies, autoimmune disease, and malignancy, the autoinflammatory hypothesis was considered. He started prednisolone 1mg/kg/day, with resolution of the clinical symptoms and inflammatory markers improvement.

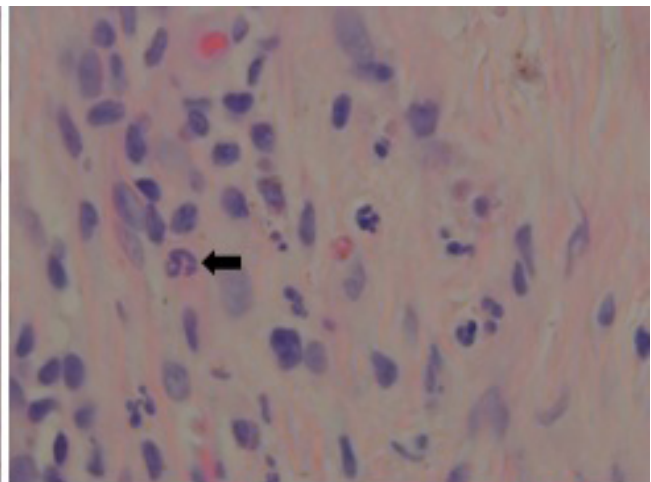
In November 2018, after tapering prednisolone to 10 mg/day, he relapsed with non-itchy urticarial rash, fever, arthralgia, fatigue, and inflammatory response. At this time, a punch skin biopsy was performed. Histological exam (figure-2) revealed eosinophils and mild-moderate dermis neutrophilic infiltration without vasculitis or dermal edema, consistent with neutrophilic dermatosis, ruling out urticarial vasculitis or Sweet syndrome. Given disease relapse and corticotherapy dependence, methotrexate was initiated. In February 2021, he remains asymptomatic under methotrexate 7.5 mg weekly plus prednisolone 2.5 mg daily with normal ferritin and inflammatory parameters and stable monoclonal component. The diagnosis remains as an autoinflammatory disorder, within the spectrum of AOSD and variant-SchS presented as rash and fever of undetermined origin (FUO).

non-specific inflammatory nature are common unspecified signs^{1, 3, 6} and older adults frequently present without classic presentation in the medical literature⁵. Fever, skin lesions and monoclonal gammopathy are central in this case. AOSD typically presents with a salmon-coloured maculopapular rash¹, but the appearance of atypical cutaneous manifestations is not uncommon⁵ and urticaria eruptions, a SchS main feature, was also reported^{3, 6}. Despite being an acute-phase protein, ferritin higher than 5x ULN in the presence of fever and arthralgia has a high positive predictive value for AOSD⁷. Monoclonal gammopathy, particularly IgG, affects 5% of general population aged 70 and older, with higher incidence over 85 years. This raises the question of whether gammopathy is an incidental diagnosis in this patient or plays a role in the pathophysiology. Less than 10% of SchS (IgG variant) have IgG type monoclonal gammopathy. However, considering that the initial definition of SchS did not include IgG, prevalence may be higher than previously reported⁸. Conventional therapy remains NSAIDs, corticosteroids, and immunosuppressants with advances favoured the use of biologic agents in severe or refractory disease¹. Despite somatic mutations were identified in both SchS and AOSD, they have an unclear role in the pathogenesis, and the mainstay of diagnosis is clinical assessment^{9,10}. Unfortunately, this tool was not yet available in our hospital.

Figure 2. Punch skin biopsy with mild to moderate neutrophilic infiltration on dermis (arrow), without vasculitis or dermal edema (H&E). With the courtesy of MD Julião, Maria José.



H&E, x400



H&E, x1000

DISCUSSION

The systemic autoinflammatory syndromes are rare and not fully understood autoinflammatory disorders which represent a diagnostic challenge in cases of FUO particularly in the elderly, because of its earlier age of onset^{1, 2}. So, a diagnosis delay can be occurred, ranging from several months to 20 years³. Furthermore, fever is a common sign of other more frequent infectious, malignant, and autoimmune conditions as discussed for this case. In this article we focus on uncommon cause of fever in the elderly - AOSD and SchS - and its potential clinical overlapping (table 2). Skin lesions, arthralgia, multiorgan presentation, and

CONCLUSION

In conclusion, the diagnosis of autoinflammatory disorders requires exclusion of autoimmune, malignant and infectious diseases and the diagnosis can be hindered by atypical clinical manifestations in the elderly. AOSD and IgG-variant SchS are rare systemic entities with shared clinical features that, in the light of current guidelines, may fulfill diagnostic criteria of both disorders. Possibly, they occupy a contiguous position in the clinical spectrum of not fully understood disorders, representing a diagnostic challenge for the medical team and emerging as an unexpected cause of fever, highlight the need for more characterization in the elderly.

Table 2. AOSD and IgG-variant SchS diagnosis according current criteria [1, 3, 5-7]

Yamaguchi (1992) AOSD criteria	Fautrel's (2002) AOSD criteria	Strasbourg (2012) IgG-variant SchS
5 criteria (≥2 major)	4 Major or 3 Major plus 2 Minor	2 Major plus 3 Minor
Sensitivity – 96.2%	Sensitivity – 80.6%	Sensitivity – 93%
Specificity – 92.1%	Specificity – 98.5%	Specificity – 97%
Major Diagnostic Criteria		
Skin rash Fever (≥39oC) for ≥1 week Arthralgia (≥2 weeks) Granulocyte leukocytosis	Fever (≥39oC) Transient rash Arthralgia ≥ 80% neutrophils Glycosylated ferritin <20%	≥6 weeks urticarial rash IgG monoclonal gammopathy
Minor Diagnostic Criteria		
Sore throat (37-92%) Lymphadenopathy (33-74%) Liver (12-45%)/spleen (29-55%) enlargement Abnormal ALT/AST, ↑LDH (54-76%) Negative ANA and RF (90-100%)	Maculopapular rash (60-94%) WBC> 10 G/L (72-94%)	Intermittent unexplained fever Abnormal bone remodelling (48%) Neutrophilic dermal infiltrate High CRP and/or leukocytosis (69%)
Other clinical and analytical features of AOSD and SchS		
Anaemia (36- 65%) Pleurisy (10-53%) Pericarditis (3-37%) Weight loss (18-44%)		Arthralgia (82%) Weight loss (64%) Bone pain (29-40%) Spleen enlargement (12%) Hepatomegaly (29%) Lymphadenopathy (44%) Anaemia (56%) ↑ ESR (96%)
ANA antinuclear antibodies; RF: rheumatoid factor. WBC: White blood cells. PCR: C-reactive protein. ESR: erythrocyte sedimentation rate. LDH: lactate dehydrogenase.		

LEARNING POINTS

- Autoinflammatory syndromes represent a diagnostic challenge for the medical team and emerge as an unexpected cause of fever in the elderly.
- The diagnosis can be hindered by atypical clinical manifestations in the elderly.
- AOSD and SchS have overlapping clinical symptoms, making the exact diagnosis difficult sometimes.
- Clinical response to immunosuppressive therapy supports the autoinflammatory hypothesis.

CONFLICT OF INTEREST

The authors declare that they have no conflict of interests.

SOURCE OF FUNDING

This research had no funding sources.

ETHICAL ASPECTS

All participants submitted a consent form to be included in this study.

BIBLIOGRAFÍA

- Tomaras S, Goetzke CC, Kallinich T, Feist E. Adult-Onset Still's Disease: Clinical Aspects and Therapeutic Approach. *Journal of Clinical Medicine*. 2021; 10(4):733.
- L. Jiang, Z. Wang, X. Dai, X. Jin. Evaluation of clinical measures and different criteria for diagnosis of adult-onset Still's disease in a Chinese population. *J Rheumatol*. 2011; 38:741-746
- de Koning HD, Bodar EJ, van der Meer JW, Simon A, Schnitzler Syndrome Study Group. Schnitzler syndrome: beyond the case reports: review and follow-up of 94 patients with an emphasis on prognosis and treatment. *Semin Arthritis Rheuma*. 2007; 37 (3):137-48
- Mollaeian, A., Chen, J., Chan, N.N. et al. Adult onset Still's disease in the elderly: a case-based literature review. *BMC Rheumatol*. 2021; 5, 12
- Narváez García FJ, Pascual M, López de Recalde M, et al. Adult-onset Still's disease with atypical cutaneous manifestations. *Medicine(Baltimore)*. 2017; 96(11):e6318
- Cozzi, A., Papagrigoraki, A., Biasi, D., Colato, C., & Girolomoni, G. Cutaneous manifestations of adult-onset Still's disease: a case report and review of literature. *Clinical Rheumatology*. 2014; 35(5), 1377–1382
- Bilgin, E., Hayran, M., Erden, A. et al. Proposal for a simple algorithm to differentiate adult-onset Still's disease with other fever of unknown origin causes: a longitudinal prospective study. *Clin Rheumatol*. 2019;38:1699–1706
- Gusdorf L, Asli B, Barbarot S, et al. Schnitzler syndrome: validation and applicability of diagnostic criteria in real-life patients. *Allergy*. 2017; 72(2):177-182
- Rowczenio, D. M., Pathak, S., Arostegui, J. I., Mensa-Vilaro, A., Omoyinmi, E., Brogan, P., Lachmann, H. J. Molecular genetic investigation, clinical features, and response to treatment in 21 patients with Schnitzler syndrome. *Blood*. 2017;131(9), 974–981
- Li H, Abramova I, Chesoni S, Yao Q. Molecular genetic analysis for periodic fever syndromes: a supplemental role for the diagnosis of adult-onset Still's disease. *Clin Rheumatol*. 2018;37(8):2021-2026