

# Edema asimétrico de miembros inferiores — del historial al diagnóstico

## Asymmetric lower limb oedema – from history to diagnosis

### CASE REPORT

We present a case of a 79-year-old woman with history of rectal adenocarcinoma, previously submitted to an anterior resection in 2014. In June 2019, she was admitted in the Emergency Department complaining of exuberant oedema of the left lower limb and progressive onset prostration. At admission, she was responsive to painful stimuli, hypotensive and showed marked left lower limb swelling with crepitation to palpation. The arterial blood gas analysis evidenced metabolic acidosis and hyperlactacidemia. Analytical results included elevation of systemic inflammatory markers and acute kidney injury AKIN 3. ECG and transthoracic echocardiogram showed no alterations. Thoracic, abdominal, pelvic, and left lower limb CT images documented an intestinal suture dehiscence and a gas collection located anteriorly to the sacrum, as well as soft tissue emphysema in the left thigh, extending from the abdominal wall to the left knee, involving the subcutaneous cellular tissue and multiple muscular compartments. After a multidisciplinary-team meeting, it was decided to institute conservative treatment measures. The patient progressed to multiorgan failure and died shortly after.

Suture dehiscence and consequent intestinal content leakage is the main cause of death after colon surgery<sup>1</sup>. The most frequent complications are haemorrhage, ileus, and septic shock<sup>2</sup>. Signs and symptoms usually appear between the third day up to several weeks after surgery and its differential diagnosis with other post-operative infections may be challenging when only based on clinical evaluation! The presentation of asymmetrical lower limb oedema and post-operative timing could have been confounding factors in this case. With this, the importance of a thorough clinical and past medical history taking is evidently rooted in an internist's daily practice.

#### CONFLICT OF INTEREST

The authors declare that there is no conflict of interest in this work.

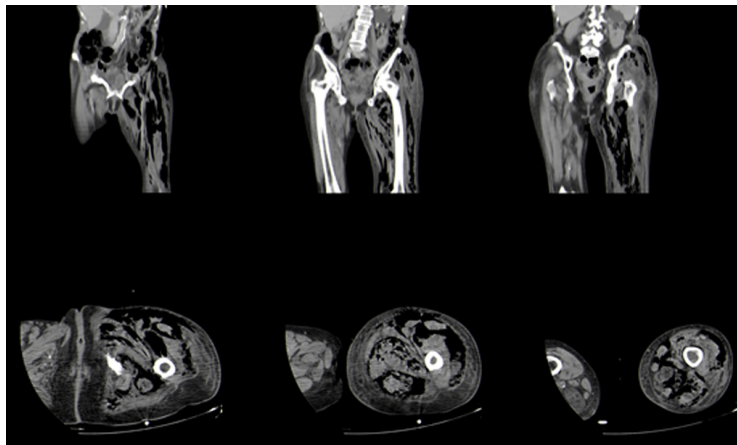
#### SOURCE OF FUNDING

This research had no funding sources.

#### ETHICAL ASPECTS

All participants submitted a consent form to be included in this study.

Figure 1. Head CT showing a soft tissue mass in the right orbit with invasion of the underlying structures (arrows).



### REFERENCES

1. Tutone SO, Hill AG, Anastomotic Leak After Colonic Resection, *Diseases of Colon & Rectum*. 2019; 62: 9-11.
2. Midura EF, Hanseman D, Davis B, Atkinson S, Abbott D, Shah SA, Paquette IM, Risk Factors and Consequences of Anastomotic Leak After Colectomy, *Diseases of Colon & Rectum*. 2015; 58: 333-8.

Catarina Couto, Gisela Evaristo Vasconcelos

*Centro Hospitalar do Tâmega e Sousa, Portugal*

Correspondencia: 73209@chts.min-saude.pt

Cómo citar este artículo: Couto C, Evaristo Vasconcelos G

Edema asimétrico de miembros inferiores — del historial al diagnóstico. *Galicia Clin* 2022; 83-1: 51

Recibido: 11/01/2021 ; Aceptado: 21/02/2021 // <https://doi.org/10.22546/64/2455>