

# Ictus isquémico agudo en un paciente con tuberculosis diseminada

*Acute ischemic stroke in a patient with disseminated tuberculosis*

## ABSTRACT

Miliary tuberculosis is an hematogenous dissemination of *Mycobacterium tuberculosis* which involves lungs, central nervous system, and lymph nodes. Stroke in tuberculous meningitis (TBM) occurs in 15-57% of patients, especially in advance stage and severe illness. We report a 21-year-old man with rapid onset confusion and right hemiparesis. Brain magnetic resonance imaging revealed acute ischemic stroke involving left internal capsule. After starting antituberculosis treatment and corticosteroids, he had a complete recovery.

**Keywords:** tuberculosis, miliary, acute ischemic stroke

**Palabras clave:** tuberculosis, miliar, ictus isquémico agudo

## CASE REPORT

A 21-years-old man presented to the emergency department with a seven-day history of fever, cough, dyspnea, and palpitations. Respiratory examination confirmed bilaterally and diffuse crackles, abdomen was soft and tender. He was tachycardic (125 bpm), with a blood pressure of 105/85 mmHg and a respiratory rate of 24 cycles/min. SpO<sub>2</sub> on air was 92% and he presented fever (38,7°C).

Laboratory tests confirmed an elevated C reactive protein (45 mg/l) with normal renal and liver function tests. VIH was negative. A chest computed tomography (CT) showed micronodular shadowing compatible with miliary tuberculosis (Figure 1). Lumbar puncture was performed, revealing xanthochromic cerebrospinal fluid (CSF) with 150/mm<sup>3</sup> white cells, 0.23 g/l glucose and 3,11 g/l of proteins. GeneXpert MTB/RIF was positive in sputum and cerebrospinal fluid. Antituberculosis treatment associated with corticosteroids (dexamethasone 4 mg daily) and oxygen was started. Four days after his admission he presented hemiparesis in right side, weakness, and dysarthria. MRI flair sequence showed lesions in left internal capsule as areas of increased signal (lacuna stroke, Figure 2). The Angio IRM time of flight (TOF) was normal.

It was decided to continue corticosteroids for 2 months and anti-tuberculosis drugs for 9. Medical treatment was associated with rehabilitation, with a complete recovery from neurological disorder.

Miliary tuberculosis is a severe disease with an increased risk of respiratory failure, extensive neurological sequelae, and high mortality. Acute stroke may occur, and most of the infarcts are seen in the basal ganglia and internal capsule<sup>1</sup>. Cerebral events occur due to the involvement of vessel wall by inflammatory exudate leading to panarteritis with secondary thrombosis and occlusion<sup>2</sup>. Aneurismal dilatation, ruptured mycotic aneurysm and granulomatous septic embolism were rarely described<sup>3</sup>. Both CT and angio-MRI detect ischemic lesions, and diffusion weighted images (DWI) allow to define the time of lesions<sup>3,4</sup>.

Tuberculous meningitis that associates stroke have a poor clinical outcome. Corticosteroid therapy must be linked with antituberculosis drugs, for reducing stroke frequency and hydrocephalous<sup>5</sup>.

Figure 1

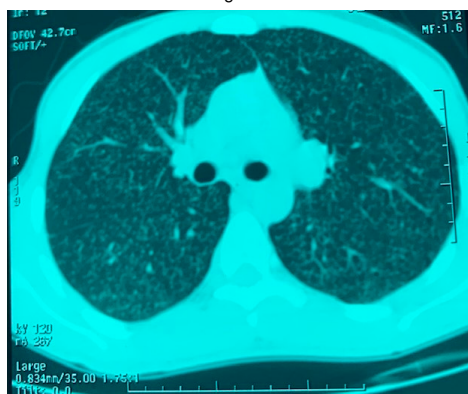
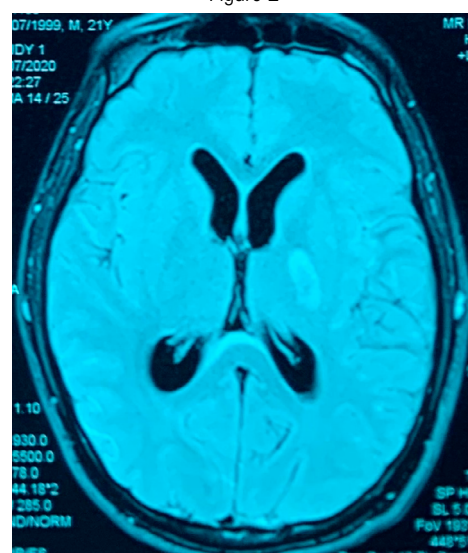


Figure 2



## REFERENCES

- Misra UK, Kalita J, Maurya PK. Stroke in tuberculous meningitis. *J Neurol Sci.* 2011;303(1-2):22-30.
- Del Brutto OH. Infections and stroke. *Handb Clin Neurol.* 2009;93:851-872.
- Lammie GA, Hewlett RH, Schoeman JF, Donald PR. Tuberculous cerebrovascular disease: a review. *J Infect.* 2009;59(3):156-166.
- Singh B, Garg RK, Singh MK, et al. Computed tomography angiography in patients with tuberculous meningitis. *J Infect.* 2012;64(6):565-572.
- Thwaites GE, Macmullen-Price J, Tran TH, et al. Serial MRI to determine the effect of dexamethasone on the cerebral pathology of tuberculous meningitis: an observational study. *Lancet Neurol.* 2007;6(3):230-236

## Bouchentouf Rachid

*Pulmonology department, Avicenna Military Hospital. Marrakech, Morocco*

Correspondencia: bouchentouf\_rachid@yahoo.fr

Cómo citar este artículo: Rachid B

Ictus isquémico agudo en un paciente con tuberculosis diseminada. *Gaceta Clin* 2021; 82-3: 177

Recibido: 29/7/2020; Aceptado: 15/4/2021 // <https://doi.org/10.22546/62/2354>