

Paget-Schroetter Syndrome

A 34-year-old man, kickboxing, presented on emergency room with 24 hours of sudden onset right upper extremities (RUE) pain, swelling and heat after vigorous exercise with that member, without trauma. He was hemodynamically stable, with RUE edema. Color doppler showed right axillary, subclavian and jugular veins thrombosis. Computed tomographic pulmonary angiography confirmed the findings, associated to acute bilateral pulmonary embolism at the level of the segmental branches (Figure 1 and 2). Excluded secondary causes of venous thrombosis of the upper limb. As described on literature on that season, he completed 6 months with anticoagulation with symptoms resolution.

Paget-Schroetter Syndrome is an effort thrombosis more common in young athletes without significant comorbidities¹. Symptom onset is usually acute or sub-acute and not infrequently can be nonspecific. Color doppler is the least invasive and least costly exam, with adequate sensitivity and specificity for diagnosis. Treatment include anticoagulation with or without revascularization therapy, such as thrombolysis, endovascular or surgical therapy^{2,3}. Complications include pulmonary embolism, present at 3% of effort thrombosis⁴. However, irrespective of the relative risk, the risk of pulmonary embolism with effort thrombosis is real and significant⁵. It's a clinical condition with impact on the patient's quality of life.

References

1. Ilhan E, Ture M, Yilmaz C, Arslan M. Subclavian Vein Thrombosis Extending into the Internal Jugular Vein: Paget-von Schroetter Syndrome. *J Clin Med Res.* 2009 Aug;1(3):178-80.
2. Thompson JF, Winterborn RJ, Bays S, et al. Venous thoracic outlet compression and the Paget-Schroetter syndrome: a review and recommendations for management. *Cardiovasc Intervent Radiol.* 2011;34(5):903-910.
3. Alla VM, Natarajan N, Kaushik M, Warriar R, Nair CK. Paget-schroetter syndrome: review of pathogenesis and treatment of effort thrombosis. *West J Emerg Med.* 2010 Sep;11(4):358-62.
4. Mark E. Archambault, DHSc, PA-C; Allison Chila; Lauren Lundin; Rachel Walker. Recognizing primary effort thrombosis in primary care. *JAAPA Journal of the American Academy of Physician Assistants.* *J Clin Med Res.* 2009;1(3):178-180.
5. Yagi S, Mitsugi M, Sangawa T, Akaike M, Sata M. Paget-Schroetter Syndrome in a Baseball Pitcher. *Int Heart J.* 2017.

Diagnóstico

Paget Von Schrotter syndrome and Pulmonary thromboembolism

Sara Pinto, Ana Raquel Ramos

Centro Hospitalar Vila Nova de Gaia Espinho. Portugal

Correspondencia: sarapinto.gr@gmail.com

Cómo citar este artículo: Pinto S, Ramos AR
Paget-Schroetter Syndrome. *Galic Clin* 2019; 80 (3): 61

Recibido: 06/09/2018; Aceptado: 11/09/2018 // <http://doi.org/10.22546/53/1761>

Fig. 1. Computed tomographic pulmonary angiography showed showed right axillary, subclavian and jugular veins thrombosis (red arrows).

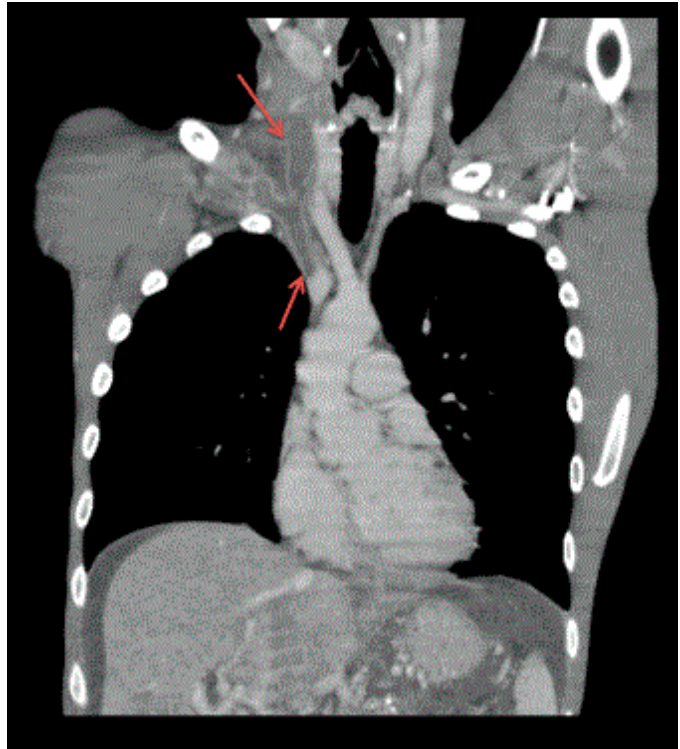


Fig. 2. Computed tomographic pulmonary angiography with different views. We can see right axillary, subclavian and jugular veins thrombosis (A, B, C), started on origin of subclavian vein (d) and pulmonary embolism (E).

