

Adult Onset Still's Disease: A rare diagnosis of undetermined febrile syndrome.

Bráulio Gomes, José Pedro Leite, Sofia Rodrigues Sousa, Dilva Silva

Hospital Geral, Centro Hospitalar e Universitário de Coimbra

Abstract

Adult Onset Still's Disease (AOSD) is a rare, systemic inflammatory disease. Its main manifestations consist of fever, arthralgias and evanescent rash and the diagnosis is essentially clinical. The authors present a case of a 43-year-old woman admitted to the Emergency Department because of fever, odynophagia and arthralgia for about 2 weeks. Complementary diagnostic tests showed elevation of C-Reactive Protein (CRP) and leukocytosis. After exhaustive investigation, the diagnosis of AOSD was made. The authors intend to alert to the importance of the inclusion of this pathology in the differential diagnosis of undetermined febrile syndrome.

Keywords: Adult Onset Still Disease. Unknown Origin Fever. Polyarthralgias. Exanthem

Palabras clave: Enfermedad de Still del adulto. Fiebre de origen desconocido. Poliartralgias. Exantema

Introduction

Adult Onset Still's Disease (AOSD) is a systemic inflammatory disease of unknown etiology. Its main clinical features are fever, arthralgia or arthritis, and an evanescent salmon color rash.

It is a rare disorder, with reported incidences ranging from 1 to 34 cases per million people. Age distribution is bimodal, most frequently affecting young adults between 15-25 years and 35-45 years.²

The fever usually presents with a daily pattern, with high peaks around 39°C. As for arthritis the predominantly affected joints are the knees, wrists, ankles and hands.¹ The rash is generally coincident with febrile peaks, manifesting itself in the trunk and proximal extremities.¹ The typical manifestations of AOSD are arthralgias, evanescent cutaneous rash, spiking fever and odynophagia. Other signs and symptoms, such as myalgias, weight loss, lymphadenopathy, hepatosplenomegaly, pleuritis, myocarditis, and pericarditis are also described.²⁻⁴

Laboratory findings in adult Still's disease are non-specific. Those findings consist of elevated inflammatory parameters, namely C-reactive protein and erythrocyte sedimentation rate, as well as neutrophilic leukocytosis. Liver enzymes may also be abnormal. The ferritin assay is of particular utility in the diagnosis of this pathology because its value is usually markedly increased, at least 5 times the normal range. Some studies suggest the use of this parameter as a marker of disease activity.^{2,3}

If present, typical image findings on CT scan and joints X-ray are hepatosplenomegaly and erosions in the affected joints. However, these abnormal findings are rare.³

There are numerous classification criteria. The most commonly accepted are the Yamaguchi criteria (table 2) with a

sensitivity of 93.5%. These are divided into major and minor criteria. For the diagnosis to be established, five items must be present, of which at least two must be major criteria (Table 2).³ Non-steroidal anti-inflammatory drugs (NSAIDs), corticosteroids and disease-modifying antirheumatic drugs (DMARDs) are the main treatment options for AOSD.^{3,5}

NSAIDs and corticosteroids are the first choice. Although NSAIDs are inefficient in controlling the disease in the vast majority of patients (80%), corticosteroids present as an effective tool when used as monotherapy (60%). The recommended starting dose is 0.5-1 mg/kg/day of prednisolone.

Methotrexate is the most widely used DMARD. It induces therapeutic response in about 70% of patients. In addition to the clinical response, it has a corticoid-sparing effect.^{2,3}

In patients refractory to DMARDs, new biologic therapy may also be used. Anakinra, tocilizumab, infliximab, etanercept and adalimumab can be used to treat refractory AOSD.^{2,3} The evolution of AOSD follows one of three patterns:

- Monophasic / Monocyclic - a single episode of disease, which can last weeks to months, with subsequent complete resolution.
- Systemic intermittent - recurrent episodes that may or may not affect the joints
- Chronic - persistent polyarthritis with joint destruction

The most frequent pattern is the chronic, affecting about 40% of patients.

During the course of the disease, potentially life-threatening complications such as macrophage activation syndrome may still arise, requiring close follow-up.²

Despite its rarity, it is a diagnosis that should not be overlooked in the study of undetermined febrile illness.

Table 1. Laboratory test results at admission and discharge

Complementary diagnostic exams	Result (reference range)
Auto-immunity/Others	
Rheumatoid factor	< 11 IU/mL (< 20 IU/mL)
Anti-nuclear antibodies	Negative
AB. anti- SSA60,SSB,Sm,RNP,Sci70, JO1	Negative
c-ANCA and p-ANCA	Negative
Complement C3 e C4	Normal
Erythrocyte sedimentation rate (ESR)	78 mm/1 st h
Angiotensin Conversion Enzyme (ACE)	53 U/L (8-52 U/L)
Immunoglobulin	No changes
Electrophoretic proteinogram	No changes
Ferritin	16974 ng/mL (10 – 120 ng/mL)
Urinalysis	No changes
Infectious diseases	
Cytomegalovirus	Absence of specific antibodies
Epstein-Barr Virus	Evidence of previous infection
Chlamydia trachomatis	Absence of specific antibodies
Rickettsia - conorii	Negative
Hepatitis B Virus	Absence of specific antibodies and antigens
Hepatitis C Virus	Absence of specific antigens
Human Immunodeficiency Virus	Absence of specific antibodies and antigens
Coxsackie virus	Absence of specific antibodies
Interferon Gama (Quantiferon)	Infection to M.tuberculosis not likely
Bengal rose test	Negative
Anti-streptolysin O titer	Normal
Blood cultures	Negative
Urine culture	Negative

Clinical case

The authors present the case of a 43-year-old woman admitted to the Emergency Department with a 19 day history of fever, arthralgia and odynophagia. Fever had a daily pattern with peaks of 39°C occurring in the evening. The arthralgias were symmetrical, non-migratory, with inflammatory pattern, located to the knees and wrists. Right before the referred symptoms, the patient had been treated for tonsillitis with two consecutive antibiotic regimens, with little to no improvement.

By the 3rd day of symptoms, she reports a trunk and limbs exanthema coincident with febrile peaks with simultaneous resolution. There are no other relevant pathological or familial antecedents reported.

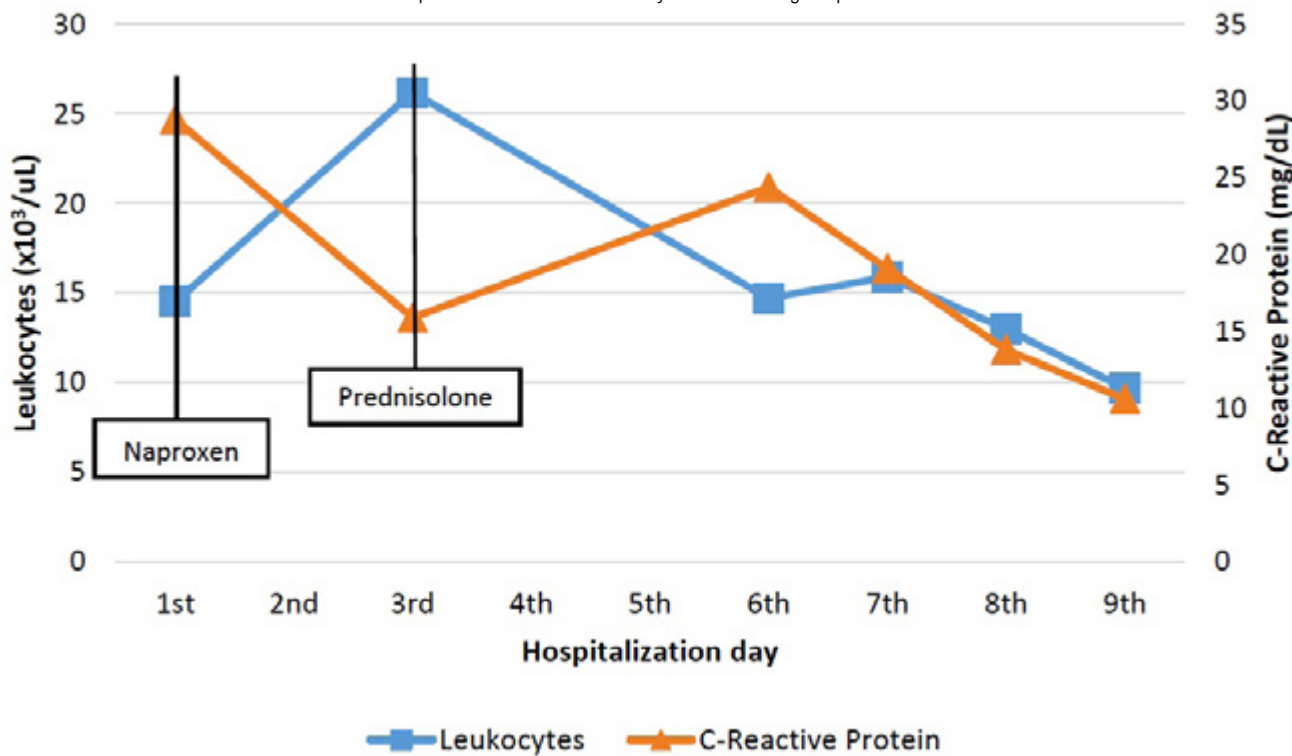
Physical examination revealed the presence of salmon colored maculopapular rash in the trunk and proximal limbs. She had no heart murmurs, palpable adenopathies or any abdominal organomegaly.

Complementary diagnostic tests (Table 1) revealed the presence of leukocytosis (14500/ μ L) with neutrophilia (85%) and marked elevation of C-reactive protein (28.8 mg/dL).

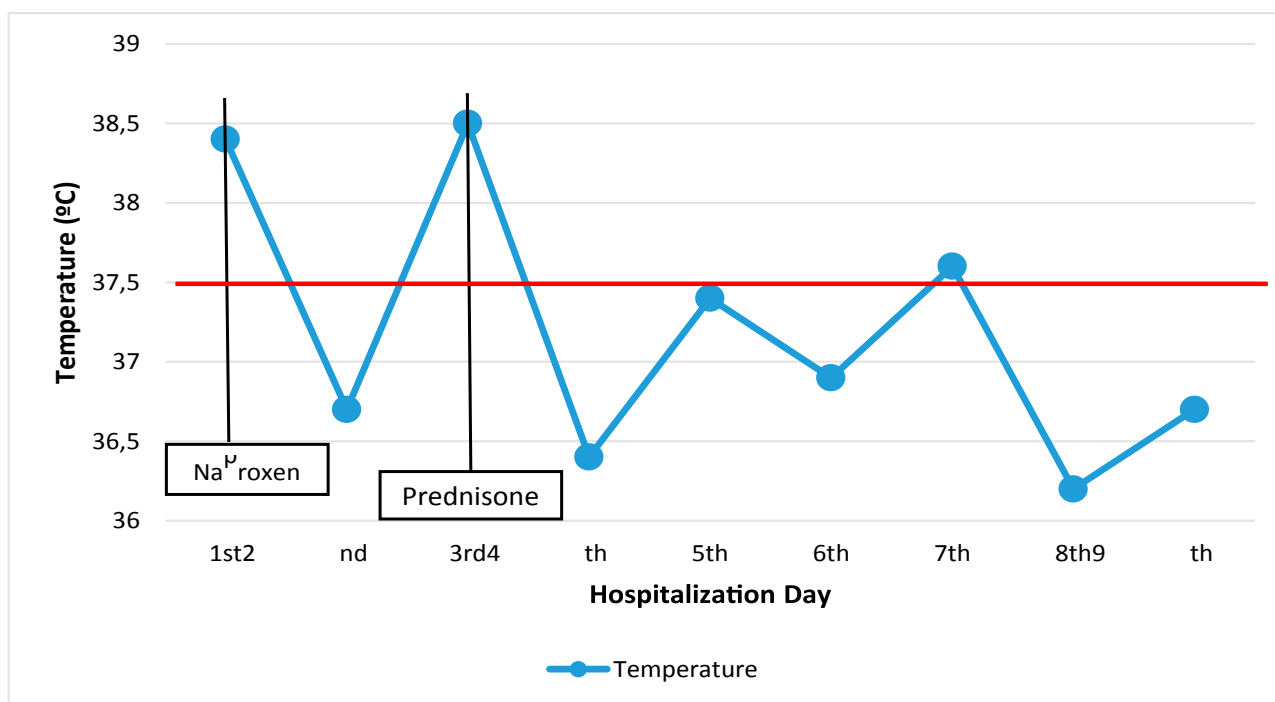
Infectious causes, both bacterial and viral, were excluded. The transthoracic echocardiogram identified the presence of a slight, circumferential pericardial effusion 8mm thick, and excluded the presence of valvular vegetations. Ferritin assay was 16974 ng/mL for an upper limit of normal of 120 ng/mL.

Given the laboratory and imaging findings as well as clinical manifestations, the diagnosis of AOSD was considered the most likely even though other autoimmune diseases had to be ruled out. It is noteworthy that the screening for anti-nuclear antibodies (ANA) and rheumatoid factor (RF) were negative, as were the assay of autoantibodies to extractable nuclear antigens (ENA) and antineutrophil cytoplasmic antibodies (ANCA). Cervical, thoracic, abdomi-

Graph.1. Evolution of inflammatory markers during hospitalization.



Graph.2. Evolution of temperature during hospitalization.



nal and pelvic computed tomography scan (CT-Scan) was also performed to exclude an occult cancer as the cause of the febrile syndrome. Besides the previously mentioned pericardial effusion, there were no other abnormal findings.

The patient was initially treated with naproxen 500mg twice daily for 3 days, maintaining low fever and arthralgias. At the third day of hospitalization, prednisolone 0.5mg/Kg/day with progressive clini-

cal and laboratorial resolution. She was discharged at the ninth day of hospitalization (graph 1 and 2).

Discussion

Regarding the typical manifestations of AOSD, our patient presented them all. Beside those, pericardial effusion was also found. The clinical case presented brings together all the usual la-

boratory findings of AOSD. The marked elevation of ferritin that the patient presented was an important guide for the correct diagnosis. Glycosylated ferritin, which is generally low in this disease, is a valuable tool for the correct diagnosis and should be measured when available.

Our patient presented with 4 major criteria and 2 minor criteria. The 2 criteria that our patient didn't met were liver dysfunction and lymphadenopathy or splenomegaly. Yamaguchi's classification requires the exclusion of alternative diagnosis, such as infectious diseases, malignant tumors, vasculitis and connective tissue diseases, which was effectively done. In fact, the exhaustive exclusion of other diagnosis that could explain the clinical picture is a strength that could be mentioned about this clinical report. Although unlikely, lymphoma should have been excluded.

Even though the clinical and laboratory findings pointed toward AOSD, it is an exclusion diagnosis. This makes choosing a treatment a difficult step. An infection is always a possibility and for that reason, we decide to treat our patient with NSAID. However, clinical response was not favorable. As the possibility of infection was ruled out, we started prednisolone 0.5mg/Kg/day. With this approach disease control was achieved. After that, prednisolone was slowly tapered to 7,5 mg/day.

In the three month follow-up the patient presented no symptoms of AOSD. We verified normalization of inflammatory markers. For the time being, it can be classified as a monophasic/monocyclic. However, regular evaluation of the patient should be maintained.

Table 2. Yamaguchi classification criteria.

Major Criteria
Fever of 39°C or above for at least 1 week
Arthralgia for at least 2 weeks
Salmon color evanescent rash
Leukocytosis above 10000/ μ L and neutrophils higher than 80%
Minor criteria
Odynophagia/Pharyngitis
Lymphadenopathy and/or splenomegaly
Liver dysfunction
Negative rheumatoid factor and antinuclear antibodies

Conclusion

Adult Onset Still's Disease is a rare disease that must be considered in the workup of an unknown origin febrile syndrome.

The diagnosis is based on clinical manifestations, requiring a high degree of suspicion. It also requires an exhaustive study to exclude diseases that may present with the same features but requiring a completely different approach.

The disease is usually controlled with the use of corticosteroids. Adequate follow-up is important to evaluate treatment response and rapidly manage its' complications.

References

1. Sethuraman VK, Balasubramanian K, Viswanathan S, Aghoram R. Inadvertent Skipping of Steroids in Septic Shock Leads to a Diagnosis of Adult Onset Still's Disease. *Cureus*. 2017;9: e978.
2. Castañeda S, Blanco R, González-Gay MA. Adult-onset Still's disease: Advances in the treatment. *Best Pract Res Clin Rheumatol*. 2016;30: 222–238.
3. Agha-Abbaslou M, Bensaci AM, Dike O, Poznansky MC, Hyat A. Adult-Onset Still's Disease: Still a Serious Health Problem (a Case Report and Literature Review). *Am J Case Rep*. 2017;18: 119–124.
4. Guilpain P, Le Quellec A. About the complexity of adult onset Still's disease... and advances still required for its management. *BMC Med*. 2017;15: 5.
5. Ferri FF. *Ferri's Clinical Advisor 2017: 5 Books in 1*. Elsevier Health Sciences; 2016.